

THEY ARE AMONG US...
JUST LOOK AROUND
AND

FIND THEM

EBBA BUFFONE, NEUROLOGIA
OSPEDALE DI BUSSOLENGO

INTRODUCTION

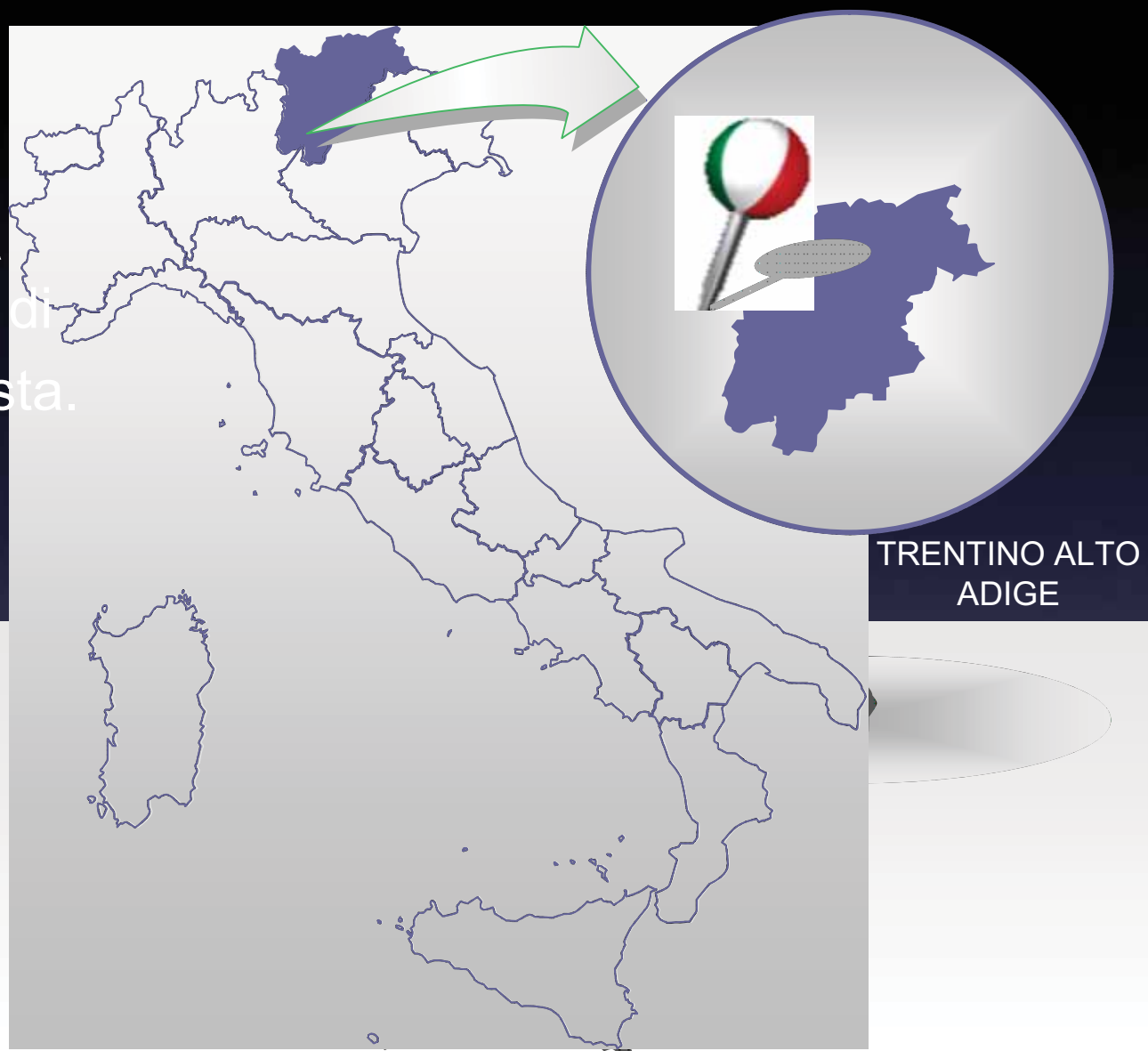LYSOSOMAL STORAGE DISEASES GENERALLY ARE DISTINGUISHED INTO SEVERE AND ATTENUATED PHENOTYPES ACCORDING TO THE INVOLVEMENT OF CNS.

HOWEVER, MPSVI AND MPIV STILL RECOGNIZE SEVERE AND ATTENUATED FORMS BASED MAINLY ON SKELETAL ALTERATIONS.

FOR THIS REASON, IN MPSIV AND VI, IF THE DISEASE IS VERY ATTENUATED IT CAN BE CONFUSED WITH A NON-METABOLIC CONDITION, RATHER DUE TO RHEUMATHOLOGIC OR ORTHOPEDIC ORIGINS.

HERE WE PRESENT THE CASE OF TWO SISTERS MISDIAGNOSED FOR MORE THAN 30 YEARS.

La Famiglia è originaria di Trafoi, piccolo paesino di montagna, della Val Venosta.



IL LUOGO DI NASCITA

CASE HISTORY

MADRE: Nata 1943, sindrome del tunnel carpale dx>sn.
ottava di nove fratelli (8F-1M) da differenti padri (5).

PADRE: Nato 1940 no major clinical history

Three Daughters: Born in 1970, 1971, 1973

FIRST SIBLING: B. L. 30.05.1970. HIGHT CM.150

Pre-term, Recurrent ENT infections. Facies sui generis, joint stiffness, claw hands, hip dysplasia. Two successful pregnancies (1F-1M), caesarian delivery due to the hips conformation. She is now pregnant for the third time. She has been evaluated only for endocrinological and rheumatological problems, always normal values. Mild LVH, Mild Mitralic and aortic insufficiency with moderate stenosis. She always suffered for "breath shortness". Employed as waitress in the family restorant.

SECOND SIBLING: B. Da.1971 HIGHT: CM 168

Born at term, obesity hyrsutism. Carpal tunel, bilateral.

THIRD SIBLING: B. Do. 1973. HIGH cm 145
Born at term. At 5y femur fracture and claudicatio. At 7y hip surgery for right hip dysplasia.

Short stature, facies sui generis, joint stiffness, claw hands, dyplasia. At 8y surgery for left hip dysplasia. At 13 y of age second bilateral surgery for hip deformities. Several medical counselling for skeletal and bone pain problems. Employed as Nurse ! in the emergency room of a small hospital in the far north of italy.

On April 2007: B. DO. was not able to work anymore in the emergency rooms. Management of patients was difficult for her due to joint stiffness and hand-pain.

Paramed colleagues complained with her since she was not quick enough and was not able to help patients to be transferred from bed to bed.

For this reason she was asked to work in a different environment, she was assigned to the Bolzano Regional Hospital.

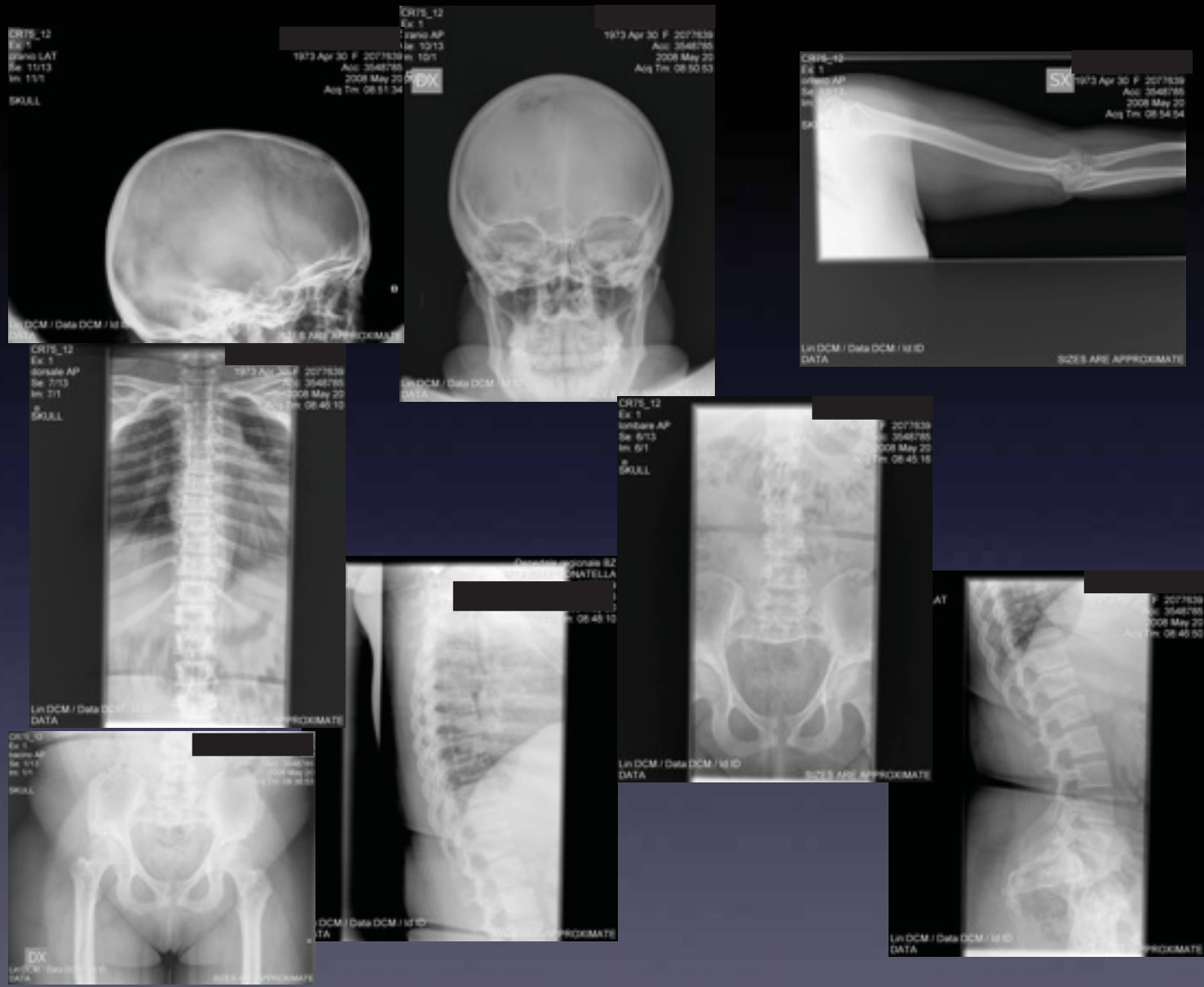URINARY GAGs A-L-IDURONIDASE
ARYLSULFATASE B

nM/mg/h(vn.18.3±5.2)

nM/mg/h (vn.129.3± 33.5)

B. L.slightly elevated 59.5 14,5 (11,2%)

B. DO slightly elevated 31.5 11.6 (9%)



B. DO

SOMATOESTHESIC EVOKED POTENTIALS

Severe compression of the motor and sensitive fibers in particular of the medial nerver in the carpal tunnel section, bilateral.

The same finding was described in the mother and in the affected sister.

HEART ULTRASOUND

Thickness of the mitral valve with noduar calcification, mild insufficiency.
Thickness of the aorthic valve with mild sthenosis and regurgitation

ABDOMEN ULTRASOUND

Liver and spleen of normal size, density no structural alterations.

SPIROMETRY

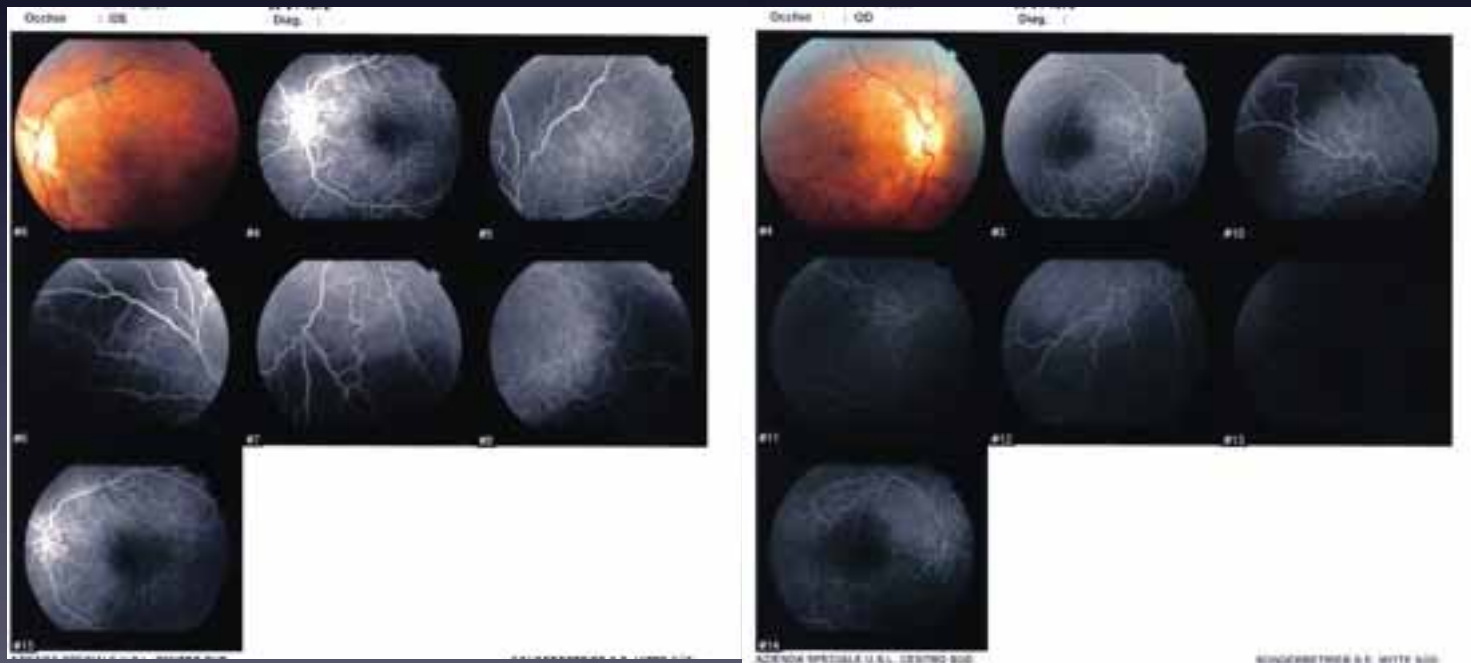
FVC 70%, FEV1 67% FEV1/FEV2 99%

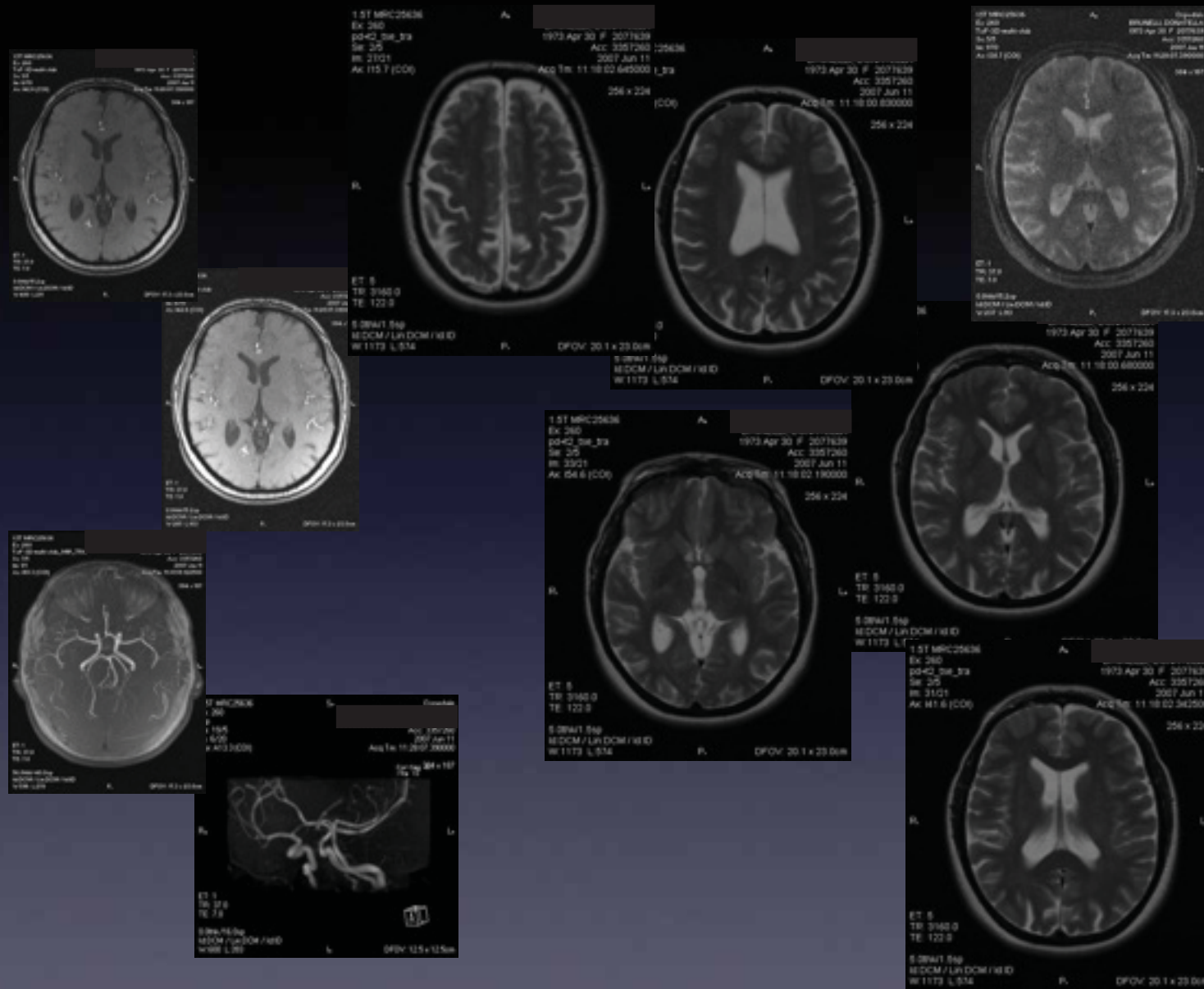
Mild respiratory restriction

OPHTHALMOLOGY

VOD 5/10, VOL 5/10, mild corneal clouding,
cotton wool-like

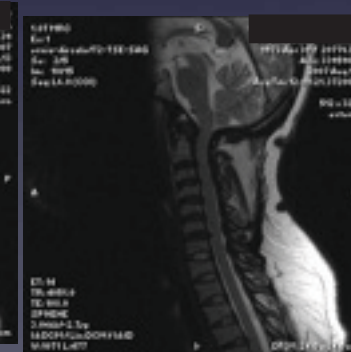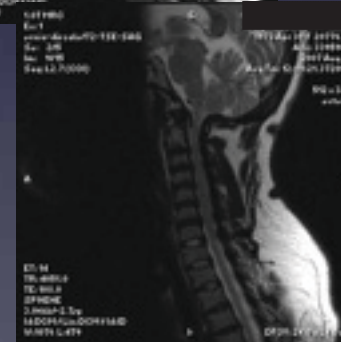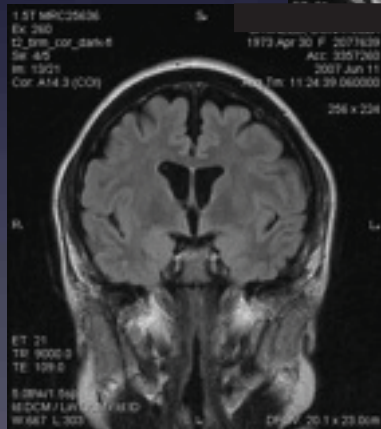
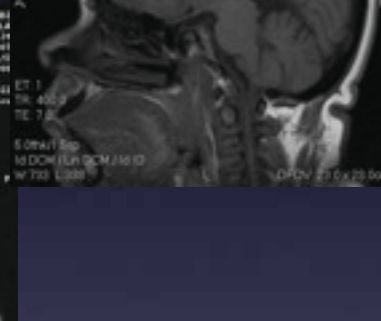
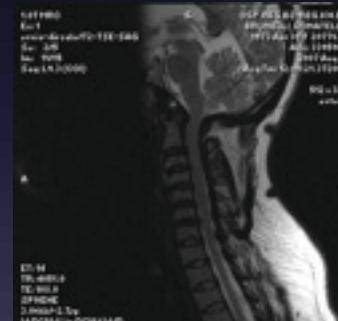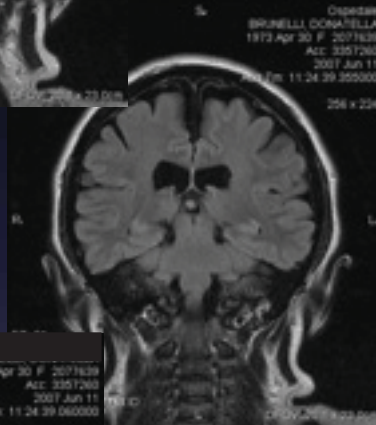
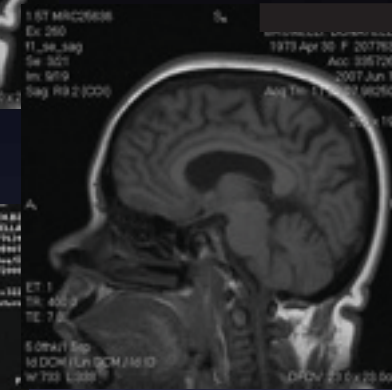
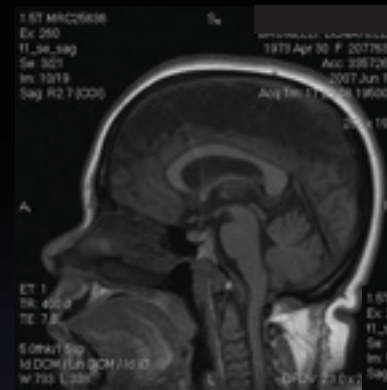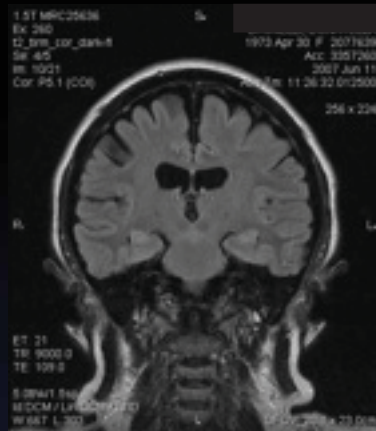
VISUAL EVOKED POTENTIALS
NORMAL

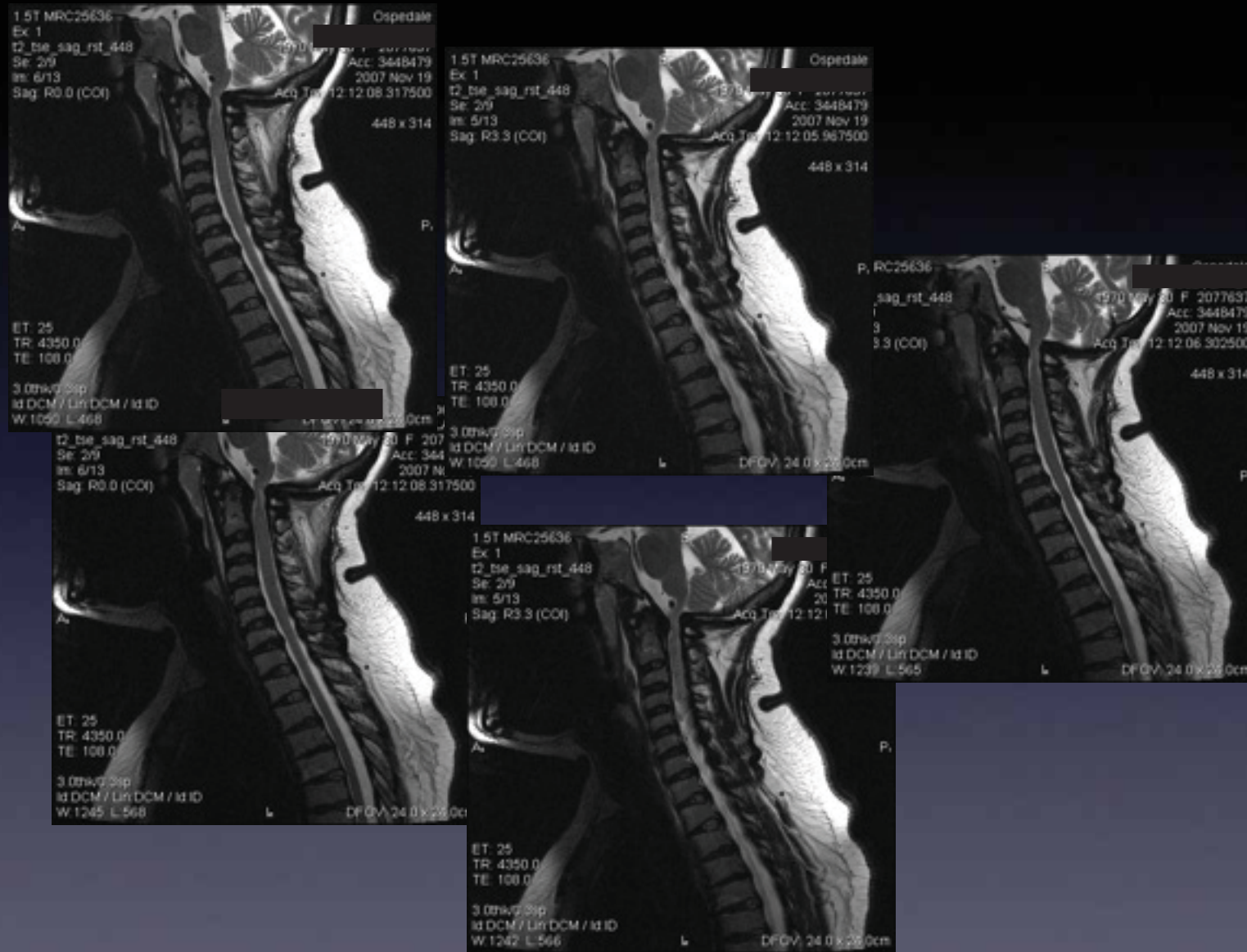




B. DO

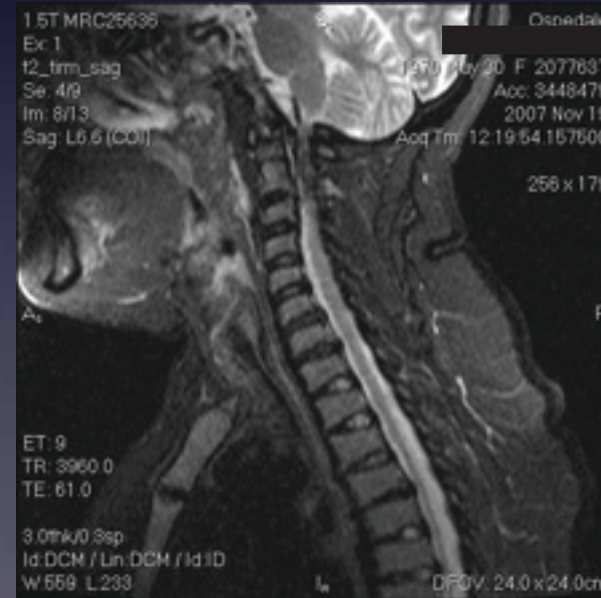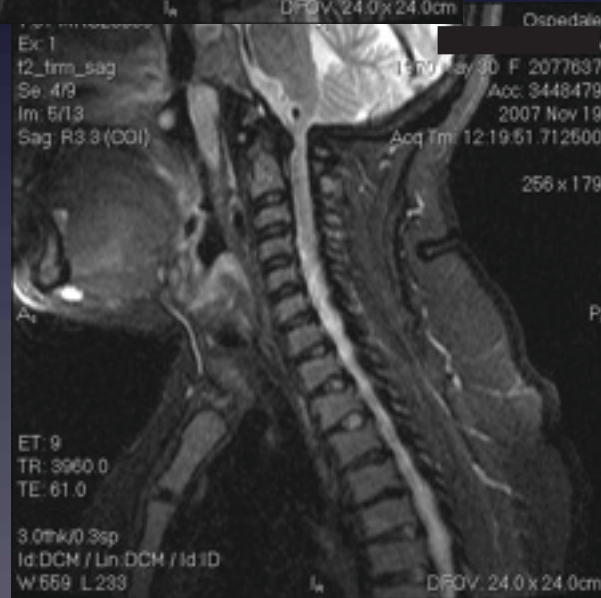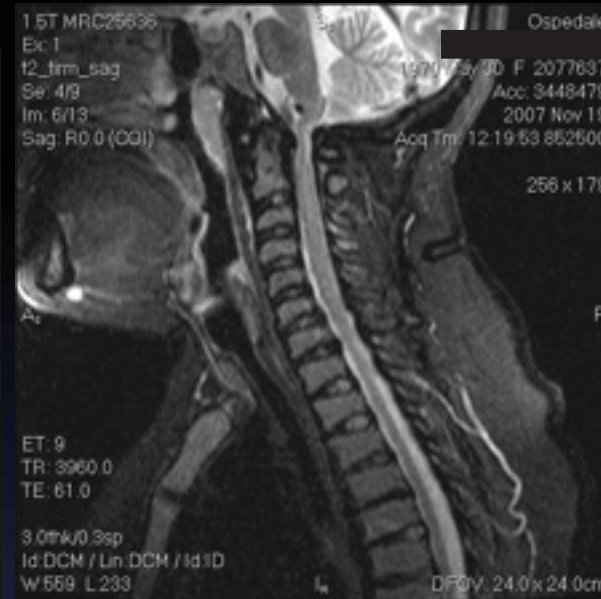
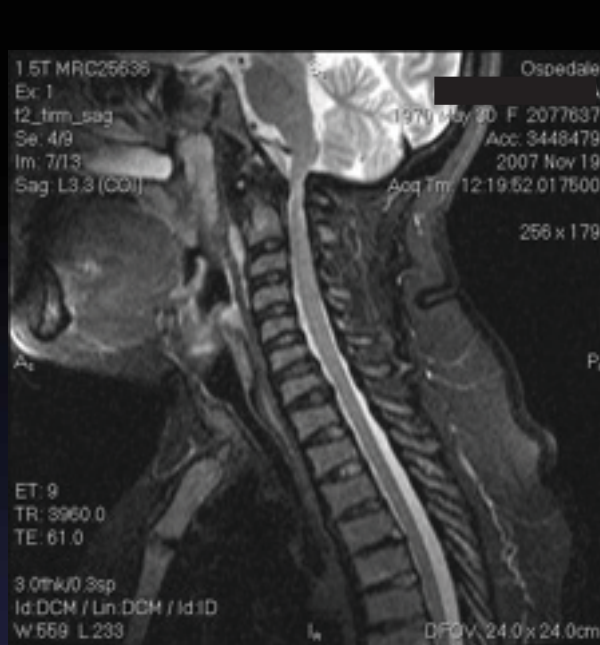B. DO

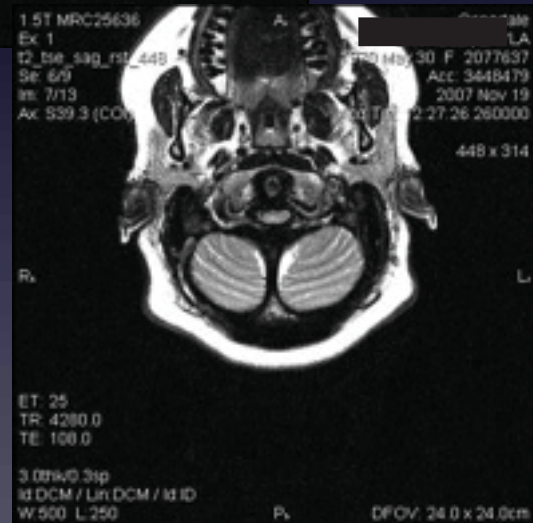
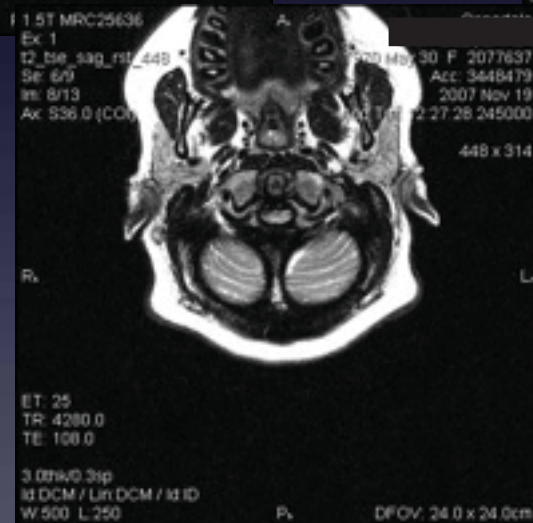
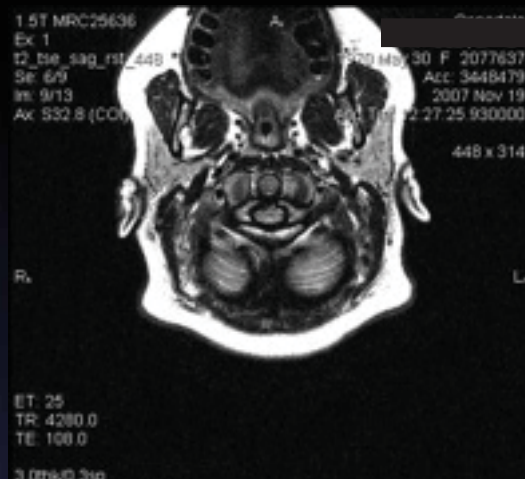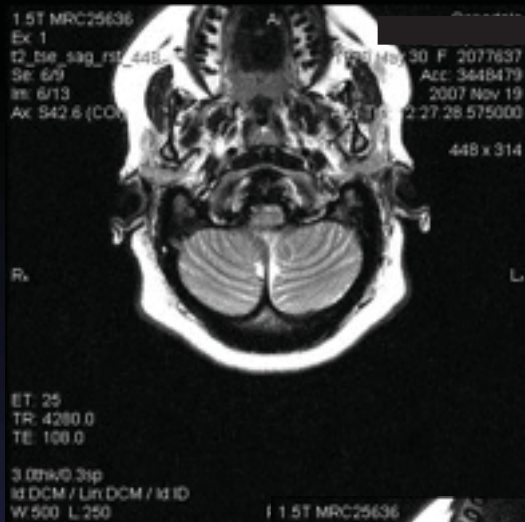


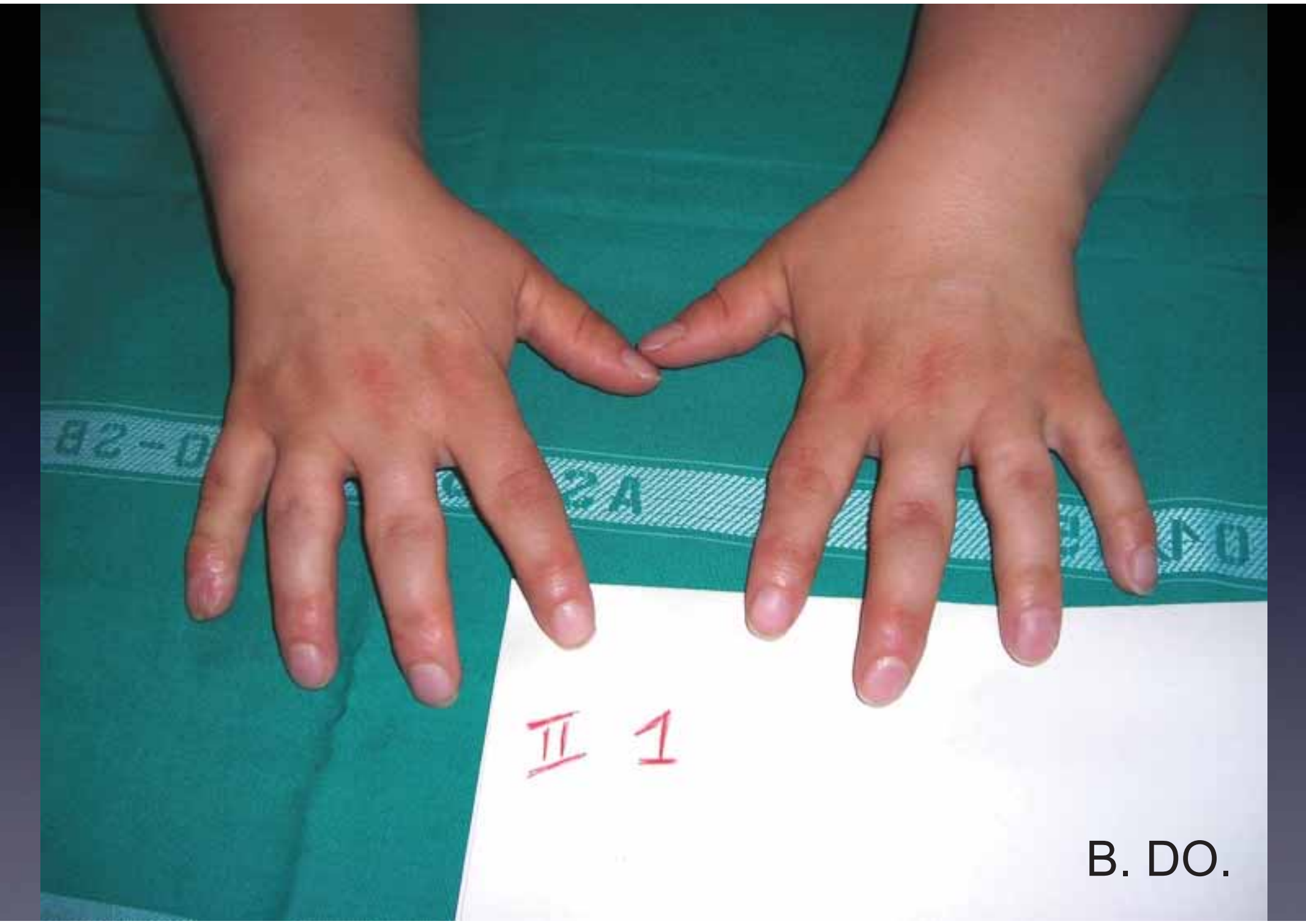


B. L.

B.L.







II 1

B. DO.

CONCLUSION

- MUCOPOLYSACCHARIDOSES MIGHT OCCUR WITH ATTENUATED PHENOTYPES WHICH MIGHT NOT BE RECOGNIZED FOR A LONG PERIOD OF TIME.
- THIS IS DUE TO THE RESIDUAL ENZYME ACTIVITY.
- IT IS CRUCIAL TO ACTIVATE INFORMATION STRATEGIES TO ALLOW THE DIAGNOSIS OF THESE PATIENTS TO HELP TO IMPROVE THE QUALITY OF LIFE WITH THERAPY.
- IT IS CRUCIAL TO DEVELOP THERAPIES FOR THE BONE DISEASE TO MODIFY THE CLINICAL HISTORY OF THE DISEASES EVEN IN ADULT PATIENTS.